

# Comparison of Marginal Bone Level Changes of Immediately Loaded Implants, Delayed Loaded Nonsubmerged Implants, and Delayed Loaded Submerged Implants: A Randomized Clinical Trial

Maria Cecília Giacomel, DDS, MSc<sup>1</sup>/ Paulo Camati, DDS, MSc<sup>1</sup>/  
Juliana Souza, DDS, MSc, PhD<sup>2</sup>/Tatiana Deliberador, DDS, MSc, PhD<sup>3</sup>

**Purpose:** The aim of this randomized clinical trial was to radiographically compare peri-implant marginal bone level changes between immediately loaded implants without the removal of an abutment placed at the time of surgery (IL), delayed loaded nonsubmerged implants (NS), and delayed loaded submerged implants (SI).

**Materials and Methods:** Patients' edentulous sites were randomly allocated to the three groups of implants so that each patient received one implant of each group. Digital periapical radiographs were obtained at baseline as well as three (T1), six (T2), and nine (T3) months after implant insertion. The mesial and distal bone crest levels adjacent to each implant were measured, and the mean values were calculated for each implant at each period. The data were statistically analyzed by repeated measures analysis of variance (ANOVA) and the Tukey test ( $P < .05$ ). **Results:** The patient sample comprised 15 subjects (13 women and 2 men; mean age: 47.7 years) with partially edentulous sites in the mandibular posterior area. Forty-five implants were inserted (15 IL implants, 15 NS implants, and 15 SI implants). There was no statistically significant difference between the three groups with regard to changes in the marginal bone level during the follow-up period. The study achieved a 93.3% cumulative survival rate for both delayed loaded groups (NS and IS) and a 100% survival rate for the IL group. **Conclusion:** In the 9-month period following the implants, no statistically significant differences were found between immediately and delayed loaded implants or between submerged and nonsubmerged implants in bone level changes in patients with partial posterior mandibular edentulism. INT J ORAL MAXILLOFAC IMPLANTS 2017;32:XXX-XXX. doi:10.11607/jomi.5353

**Keywords:** bone regeneration, dental implant, marginal bone level, osseointegration

During the last decade, implantology has become an indispensable part of dental rehabilitation, and the immediate loading of dental implants has gained great popularity. This technique is highly appreciated by patients due to the elimination of a second surgical intervention, resulting in a simplified prosthetic phase and a shortened treatment time with immediate esthetic gain.<sup>1,2</sup>

It has been previously stated that before prosthetic rehabilitation, implants should remain submerged for at least 3 months in the mandible or 6 months in the maxilla.<sup>3</sup> However, further studies have demonstrated that osseointegration and implant success may be achieved without prolonged healing periods and even after immediate loading of the implants.<sup>2,4,5</sup>

Some implant systems recommend implant submergence during the initial phase of osseointegration, advising that this recommendation may minimize the risk of infection, reduce vertical bone loss, decrease the risk of undue early loading, and prevent apical downgrowth of mucosal epithelium.<sup>6</sup>

Some studies have suggested that significant differences regarding vertical bone loss can be detected between the one-stage and two-stage implant placement techniques during the first and second year of function.<sup>6,7</sup> However, most recent studies have observed similar marginal bone level changes between immediately and delayed loading implants and/or

<sup>1</sup>Associate Professor, Positivo University Dental School, Curitiba, Brazil.

<sup>2</sup>Professor, Department of Stomatology, School of Dentistry, Federal University of Parana, Curitiba, Brazil.

<sup>3</sup>Professor of Graduate Program in Dentistry, Positivo University Dental School, Curitiba, Brazil.

**Correspondence to:** Dr Maria Cecilia Lopes Giacomel, Rua Guilherme Pugsley, 1230, ap 1001, Curitiba - PR - 80620-000, Brazil. Fax: 55 41 96031603. Email: lia\_mcl@hotmail.com

©2017 by Quintessence Publishing Co Inc.

between submerged and nonsubmerged placed implants, indicating that it is possible to obtain a high percentage of clinical success for extended periods using different protocols for implant placement and loading.<sup>5,8-11</sup>

Several surgical procedures have been proposed to minimize bone remodeling after implant insertion.<sup>10,12</sup> However, very few studies have assessed the effects of the abutment removal for prosthetic rehabilitation on marginal bone loss.<sup>12,13</sup>

The aim of this randomized clinical trial was to radiographically compare peri-implant marginal bone level changes between immediately loaded implants without the removal of an abutment placed at the time of surgery (IL), delayed loaded nonsubmerged implants (NS), and delayed loaded submerged implants (SI) for a period of 9 months after implant placement. To the best of the authors' knowledge, this is the first randomized clinical trial showing comparisons between these three dental implant procedures.

## MATERIALS AND METHODS

### Study Design and Population

Ethical approval was obtained from the Ethics Research Committee of Positivo University Dental School, Brazil.

The patients who were eligible for inclusion in this trial had partially edentulous sites in the mandibular posterior area and were between the ages of 18 and 60 years. Patients were excluded from the study if any of the following criteria was present: (1) smoking; (2) pregnancy or lactation; (3) uncontrolled systemic disorders; (4) parafunction (bruxism or clenching); (5) poor oral hygiene; (6) the presence of active periodontal disease or caries; (7) the use of bisphosphonates or any medicine that could compromise osseointegration; and (8) a need for bone reconstruction before implant insertion.

Patients were selected from the consultation clinic at the Department of Implantology at Positivo University Dental School (Curitiba, Brazil) from July 2013 to January 2014.

The sample size was calculated by using an alpha significance level of .05 and a beta level of .02 to achieve 80% of power to detect a mean  $\pm$  SD difference of  $0.6 \pm 0.5$  mm in marginal bone level changes between groups, based on the results reported in a previous study.<sup>8</sup> The sample size calculation showed that 12 patients per group were needed. To protect from possible withdrawals, a sample size of 15 patients was recruited.

For each patient, informed consent, medical history, and dental history were recorded and assessed. All participants were informed about the nature of the

study and received oral hygiene instructions before treatment. Patients were recalled monthly for oral hygiene maintenance during the observational period. Computed tomography (CT) scans were obtained before treatment for surgical planning.

Patients' edentulous sites were randomly allocated by a manually generated randomization list into three different groups so that each patient received one implant of each group. The implants of the IL group ( $n = 15$ ) were immediately loaded. The implants of the NS group ( $n = 15$ ) received delayed loading with nonsubmerged implants (placement of a healing screw). The implants of the SI group ( $n = 15$ ) received delayed loading and remained submerged during a healing period of 3 months (Fig 1).

### Surgical Procedures

All patients were instructed to take 1 g amoxicillin and 4 mg dexamethasone 1 hour before the surgical procedure. None of the patients were allergic to penicillin. Antisepsis was performed extraorally using 2% chlorhexidine mouthwash and intraorally using 0.12% chlorhexidine mouthwash for 1 minute. Local anesthesia (2% mepivacaine/adrenaline 1:100,000) was administered at the time of surgery.

All three implants (one of each group) were placed in each patient on the same day, in the same surgical procedure, and by the same experienced surgeon.

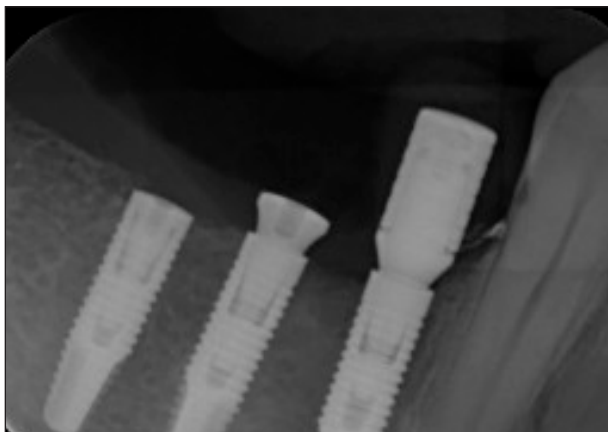
#### [AU: Initials of surgeon?]

Surgery began for all implant groups with a midcrestal incision in the edentulous area and the elevation of a full-thickness, mucoperiosteal flap to expose the crestal ridge. The implant insertion procedure followed the manufacturer's instructions and was the same for all implants since only 3.5-mm-diameter SW Morse implants (SIN-Implant System) were used. The implant length was chosen according to the bone quantity and quality at each site in each patient. All implants were placed with the implant platform at the mesial or distal bone crest level and with a mean insertion torque of 36 Ncm (Fig 1). The relative positions among the three implant methods varied between patients since the edentulous sites were randomly allocated.

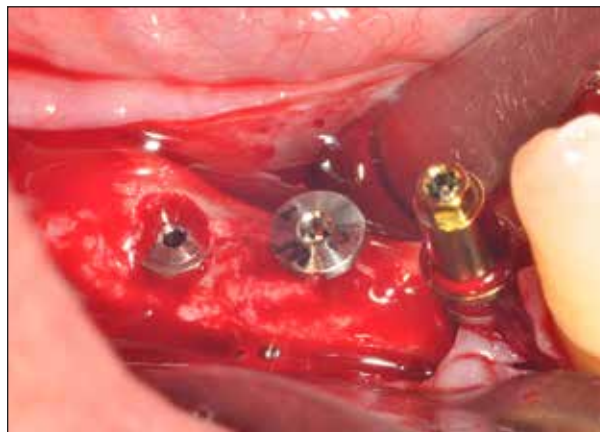After implant insertion, the definitive abutments were connected to the implants of the IL group, healing abutments were inserted in the NS group implants, and the implants of the SI group received cover screws and remained submerged for 3 months before prosthetic rehabilitation (Fig 2). Thereafter, the surgery wound was closed with simple sutures (Fig 3). Additionally, provisional acrylic resin restorations were immediately provided to the IL implants (Fig 4).

Patients were asked to use mouthwash with 0.12% chlorhexidine for 1 minute every 12 hours, starting 24 hours postoperatively and thereafter for 2 weeks. They

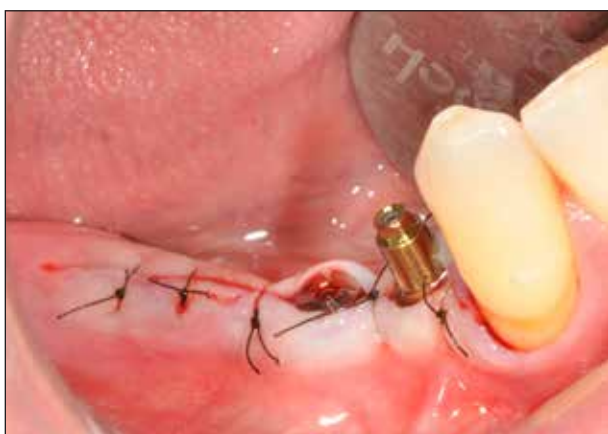[Au: Please provide larger, separate images that are layered or without arrows or type for fig 1]



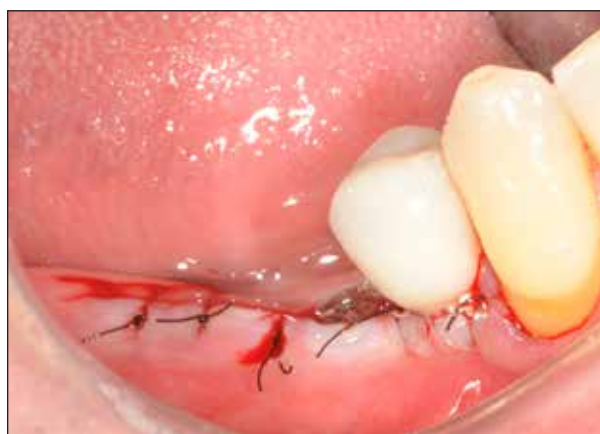**Fig 1** Periapical radiograph taken immediately after the placement of SI, NS, and IL implants, respectively.



**Fig 2** Cover screw (SI group), healing abutment (NS group), and definitive abutment (IL group) in position immediately after surgery, respectively.



**Fig 3** Soft tissue positioned and sutured into place leaving the cover screw (SI group) submerged and the definitive abutment (IL group) and the healing abutment (NS group) nonsubmerged.



**Fig 4** Provisional acrylic resin restoration cemented around the abutment in the IL group.

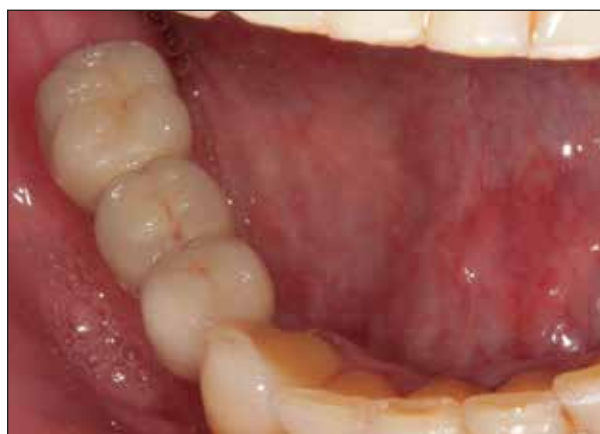were also instructed to use ibuprofen 600 mg every 8 hours for 3 to 5 days and amoxicillin 500 mg every 8 hours for 7 days. Sutures were removed 10 days after implant placement.

### Definitive Rehabilitation

After a 3-month period, the implants of the SI group went through a second surgical intervention to expose the implants. Crestal incisions and flaps were made with a minimal extension to minimize the local tissue damage. Ten days after this procedure, definitive abutments were placed in the delayed loaded implants (NS and SI groups), and provisional acrylic resin restorations were cemented. The definitive metal-ceramic restorations were delivered after 3 months of implant placement for all groups (Fig 5).

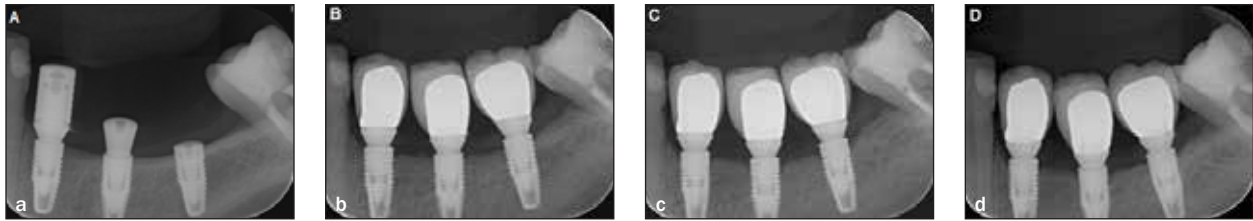
### Radiographic Analysis and Survival Rate

Standardized periapical radiographs of the implants were taken at baseline (immediately after implant




**Fig 5** Definitive metal-ceramic restorations delivered 3 months after implant placement.

[AU: Please provide larger, separate images that are layered or without arrows or type for fig 6]



**Fig 6** Follow-up periapical radiographs obtained at (a) baseline, and at (b) T1, (c) T2, and (d) T3.



**Fig 7** Paralleling device with the individually customized jig in position.

placement), and after three (T1), six (T2), and nine (T3) months of implant insertion (Fig 6). All periapical radiographs were obtained using a digital intraoral sensor (Snapshot, Instrumentarium) and a paralleling device (Indusbello). An individually customized positioning jig was produced for each patient using acrylic resin to copy the teeth adjacent to the edentulous sites and used in substitution of the rubber bite-block to stabilize intraorally the paralleling device, making it possible to achieve standardized serial radiographs (Fig 7).

The radiographs were analyzed by one blinded, calibrated operator. The marginal bone level was measured using the Cliniview 10.2.2 software (Instrumentarium). This is the same software that was used to obtain the digital radiographs, which means that no image size distortion was generated. The mesial and distal bone crest levels adjacent to each implant were measured from the coronal margin of the implant collar to the most coronal point of the peri-implant bone. An increase of this vertical distance was considered indicative of bone loss. This distance was calculated for each implant at each follow-up examination by determining the difference between baseline values. At the baseline, the bone loss value was zero for all samples.

Implant survival was defined as the absence of implant mobility and was assessed 10 days after the provisional restoration cementation and at each follow-up stage.

### Statistical Analyses

All statistical analyses were performed using SPSS 16.0 software (SPSS). Results were regarded as significant at  $P < .05$ . The mesial and the distal radiographic measurements were averaged for each implant at each period and used as a statistical element.

Descriptive statistics were used to present the results. Normal distribution was verified with the Levene test. All variables showed normal distribution. Therefore, the data obtained from each implant group and from each studied period were compared by repeated measures analysis of variance (ANOVA) followed by the Tukey test. Furthermore, the actuarial method was used to evaluate the implant survival rate. Significant differences in survival rates between groups were verified using the Log-Rank Mantel-Cox test.

## RESULTS

Fifteen patients (13 women and 2 men) with a mean age of 47.7 years (range: 30 to 61 years) were eligible for inclusion in this clinical trial. A total of 45 implants were inserted (15 IL implants, 15 NS implants, and 15 SI implants). Each patient received one implant of each group. Two patients received unilateral implants, and 13 patients received bilateral implants in the mandibular posterior area. [AU: Table 1 was deleted to conserve space since the information is in the text]

One NS group implant and one SI group implant failed at T1, 10 days after the provisional restorations were cemented. Both implants had been placed on the same patient (female), who was then excluded from the study. Both nonimmediate loading groups (NS and IS) obtained a 93.3% cumulative survival rate during the 9-month follow-up period. A 100% survival rate was observed in the IL group for the same observational period. The difference between groups was not statistically significant (Table 1).

The greatest amount of marginal bone loss was shown at T1 in all groups, with a statistically significant difference from the other stages ( $P < .01$ ). There was no statistically significant difference between the three groups regarding changes in the marginal bone level during the follow-up period ( $P = .21$ ; Table 2).



**Table 1 Actuarial Method Survival Analysis for the Groups**

| Group | Stage (x) | Subjects at start of interval (lx) | Failure during the interval (dx) | Failure rate during the interval (qx) | Survival rate during the interval (px) | Cumulative survival rate to end of interval S (tx) |
|-------|-----------|------------------------------------|----------------------------------|---------------------------------------|--|--|
| IL    | T1        | 15                                 | 0                                | 0.000                                 | 1.000                                  | 1.000  |
|       | T2        | 15                                 | 0                                | 0.000                                 | 1.000                                  | 1.000  |
|       | T3        | 15                                 | 0                                | 0.000                                 | 1.000                                  | 1.000  |
| NS    | T1        | 14                                 | 1                                | 0.067                                 | 0.933                                  | 0.933  |
|       | T2        | 14                                 | 0                                | 0.000                                 | 1.000                                  | 0.933  |
|       | T3        | 14                                 | 0                                | 0.000                                 | 1.000                                  | 0.933  |
| SI    | T1        | 14                                 | 1                                | 0.067                                 | 0.933                                  | 0.933  |
|       | T2        | 14                                 | 0                                | 0.000                                 | 1.000                                  | 0.933  |
|       | T3        | 14                                 | 0                                | 0.000                                 | 1.000                                  | 0.933  |

Where:  $(r_x = lx - wx/2)$ ,  $(q_x = d_x/r_x)$ , and  $(p_x = 1 - q_x)$

Differences between groups were analyzed by the Log-Rank Mantel-Cox test ( $P = .600$ ).

The frequencies of structures adjacent to the mesial and distal areas of the implants evaluated in the present study are presented in Table 3. The IL and SI groups had higher occurrences of implant surfaces being adjacent to teeth. These groups also presented greater bone loss than the NS group implants, but without statistical significance. Similarly, no statistically significant difference was shown regarding the distribution of the adjacent structures between groups ( $P = .09$ ).

In addition, at T3, two implants in the IL group, two implants in the SI group, and one implant in the NS group showed greater marginal bone level values than observed at baseline.

## DISCUSSION

The present clinical trial assessed and compared peri-implant marginal bone level changes between immediately loaded implants without the removal of an abutment placed at the time of surgery (IL), delayed loaded nonsubmerged implants (NS), and delayed loaded submerged implants (SI).

The study achieved a 93.3% cumulative survival rate over a period of 9 months for both of the delayed loaded groups (NS and IS) and a 100% survival rate for the IL group. There was no significant statistical difference between the three procedures involved in the present study in terms of the final survival rate (Table 1). High implant survival rates are generally expected for both immediately and delayed loaded mandibular implants.<sup>2</sup> Adequate primary implant stability seems to be a fundamental prerequisite for achieving and maintaining implant osseointegration over time.<sup>14-16</sup>

No statistically significant intergroup difference was observed regarding changes in the marginal bone level, as evidenced by similar values of bone loss observed in

**Table 2 Mean Marginal Bone Loss (mm) at T1, T2, and T3, and Comparison Within and Between Groups (Repeated-Measures ANOVA)**

| Group          | Stage (x) | Mean ( $\pm$ SD) bone loss      |
|----------------|-----------|---------------------------------|
| IL             | T1        | 1.08 <sup>A</sup> ( $\pm$ 0.51) |
|                | T2        | 0.98 <sup>B</sup> ( $\pm$ 0.67) |
|                | T3        | 0.87 <sup>C</sup> ( $\pm$ 0.21) |
| NS             | T1        | 0.89 <sup>A</sup> ( $\pm$ 0.46) |
|                | T2        | 0.75 <sup>B</sup> ( $\pm$ 0.42) |
|                | T3        | 0.77 <sup>C</sup> ( $\pm$ 0.11) |
| SI             | T1        | 1.06 <sup>A</sup> ( $\pm$ 0.59) |
|                | T2        | 1.05 <sup>B</sup> ( $\pm$ 0.59) |
|                | T3        | 0.84 <sup>C</sup> ( $\pm$ 0.19) |
|                |           | <b>P value</b>                  |
| Within-group   |           | < .01*                          |
| Between-groups |           | .21                             |
| Group X Time   |           | .39                             |

Different letters indicate statistically significant differences.

\*Statistically significant at  $P < .05$ .

**Table 3 Frequencies of Structures Adjacent to Mesial and Distal Areas of Implants in Studied Groups**

| Adjacent structure | Groups |    |    |
|--------------------|--------|----|----|
|                    | IL     | NS | SI |
| Teeth              | 16     | 11 | 16 |
| Implants           | 13     | 14 | 7  |
| Edentulous areas   | 1      | 5  | 7  |

the three groups at all stages (Table 2). These results are in agreement with other studies in the literature that compared marginal bone level changes between immediately and delayed loaded implants<sup>5,8,10,11,17</sup> as well as between submerged and nonsubmerged implants.<sup>7,10,18,19</sup>

It has been reported that the removal and reconnection of the abutment for prosthetic rehabilitation<sup>12</sup> may create a soft tissue wound with subsequent bone resorption.<sup>20</sup> However, in the present study, no statistically significant difference was found between the group where the abutment was not removed (IL) and the other two groups (NS and SI) with regard to the measurement of vertical bone loss, as demonstrated by a previous study.<sup>12</sup>

The aforementioned study found, on the other hand, that the nonremoval of the abutment resulted in a statistically significant reduction of the horizontal bone remodeling around immediately loaded implants. This parameter was not specifically assessed in the present study.

Brånemark et al<sup>3</sup> reported that one factor that can contribute to marginal bone loss is the occurrence of surgical trauma during the detachment of the periosteum. In the present study, during the second stage of treatment, the surgical reopening of all of the SI group implants was conducted with minimal crestal incision, and flaps were made with a minimal extension to minimize local tissue damage. Yet, the SI group implants showed a slightly greater, although not statistically significant, amount of vertical bone loss 3 months after this procedure (T2) compared with the groups that were not submitted to a surgical reopening stage (IL and NS).

Corroborating the results found in the present study, a recent meta-analysis concluded that the literature does not indicate any significant difference between nonsubmerged and submerged implant procedures with regard to the occurrence of postoperative marginal bone loss.<sup>21</sup> Nevertheless, although nonsubmerged implants show clinical results comparable to those of submerged implants, patient satisfaction with immediately loaded implants is usually significantly higher due to decreased surgical intervention and a simplified prosthetic phase.<sup>7</sup>

According to the criteria suggested by Brånemark et al,<sup>3</sup> implants are considered successful when they present a mean marginal bone loss of less than 1.5 mm during the first year after insertion. Therefore, it can be assumed that the three procedures studied here can be applied successfully in cases of partial posterior mandibular edentulism since the mean bone loss after 9 months of implant placement (T3) was below 1.5 mm in all groups (Table 2).

This manuscript is a preliminary report of the results. Further investigations will be conducted to the third year post-implant placement. Up to this point, it

may be stated that the protocol of submerged implant placement may be predictably replaced by the immediate loading of implants in cases where primary stability can be achieved and in the absence of parafunction. Although similar results were observed between the three procedures involved in the present study in terms of the final outcome of the implant treatment, the immediate loading protocol may provide greater comfort to the patient due to the absence of a second surgical stage and a shortened treatment time.

## CONCLUSIONS

There were no statistically significant differences regarding marginal bone level changes between immediately loaded implants (IL), delayed loaded nonsubmerged implants (NS), and delayed loaded submerged implants (SI) in patients with partial posterior mandibular edentulism who were followed for 9 months. Long-term longitudinal studies with large and representative samples are recommended.

## ACKNOWLEDGMENTS

The authors report no conflicts of interest related to this study.

## REFERENCES

- Garcia RV, Kraehenmann MA, Bezerra FJ, Mendes CM, Rapp GE. Clinical analysis of the soft tissue integration of non-submerged (ITI) and submerged (3i) implants: A prospective-controlled cohort study. *Clin Oral Implants Res* 2008;19:991–996.
- Strub JR, Jurdzik BA, Tuna T. Prognosis of immediately loaded implants and their restorations: A systematic literature review. *J Oral Rehabil* 2012;39:704–717.
- Brånemark PI, Hansson BO, Adell R, et al. Osseointegrated implants in the treatment of the edentulous jaw. Experience from a 10-year period. *Scand J Plast Reconstr Surg Suppl* 1977;16:1–132.
- Szmukler-Moncler S, Salama H, Reingewirtz Y, Dubruille JH. Timing of loading and effect of micromotion on bone-dental implant interface: Review of experimental literature. *J Biomed Mater Res* 1998;43:192–203.
- Stokholm R, Isidor F, Nyengaard JR. Histologic and histomorphometric evaluation of peri-implant bone of immediate or delayed occlusal-loaded non-splinted implants in the posterior mandible—An experimental study in monkeys. *Clin Oral Implants Res* 2014;25:1311–1318.
- Ericsson I, Randow K, Glantz PO, Lindhe J, Nilner K. Clinical and radiographical features of submerged and nonsubmerged titanium implants. *Clin Oral Implants Res* 1994;5:185–189.
- Nemli SK, Güngör MB, Aydın C, Yılmaz H, Türkcan I, Demirköprülü H. Clinical evaluation of submerged and non-submerged implants for posterior single-tooth replacements: A randomized split-mouth clinical trial. *Int J Oral Maxillofac Surg* 2014;43:1484–1492.
- Galli F, Capelli M, Zuffetti F, Testori T, Esposito M. Immediate non-occlusal vs. early loading of dental implants in partially edentulous patients: A multicentre randomized clinical trial. Peri-implant bone and soft-tissue levels. *Clin Oral Implants Res* 2008;19:546–552.

9. Kim DM, Badovinac RL, Lorenz RL, Fiorellini JP, Weber HP. A 10-year prospective clinical and radiographic study of one-stage dental implants. *Clin Oral Implants Res* 2008;19:254–258.
10. Siadat H, Panjnoosh M, Alikhasi M, Alihoseini M, Bassir SH, Rokn AR. Does implant staging choice affect crestal bone loss? *J Oral Maxillofac Surg* 2012;70:307–313.
11. Engelhardt S, Papacosta P, Rathe F, Özen J, Jansen JA, Junker R. Annual failure rates and marginal bone-level changes of immediate compared to conventional loading of dental implants. A systematic review of the literature and meta-analysis. *Clin Oral Implants Res* 2015;26:671–687.
12. Degidi M, Nardi D, Piattelli A. One abutment at one time: Non-removal of an immediate abutment and its effect on bone healing around subcrestal tapered implants. *Clin Oral Implants Res* 2011;22:1303–1307.
13. Kuppusamy M, Watanabe H, Kasugai S, Kuroda S. Effects of abutment removal and reconnection on inflammatory cytokine production around dental implants. *Implant Dent* 2015;24:730–734.
14. Ottoni JM, Oliveira ZF, Mansini R, Cabral AM. Correlation between placement torque and survival of single-tooth implants. *Int J Oral Maxillofac Implants* 2005;20:769–776.
15. De Bruyn H, Van de Velde T, Collaert B. Immediate functional loading of TiOblast dental implants in full-arch edentulous mandibles: A 3-year prospective study. *Clin Oral Implants Res* 2008;19:717–723.
16. Bergkvist G, Nilner K, Sahlholm S, Karlsson U, Lindh C. Immediate loading of implants in the edentulous maxilla: Use of an interim fixed prosthesis followed by a permanent fixed prosthesis: A 32-month prospective radiological and clinical study. *Clin Implant Dent Relat Res* 2009;11:1–10.
17. Romanos G, Froum S, Hery C, Cho SC, Tarnow D. Survival rate of immediately vs delayed loaded implants: Analysis of the current literature. *J Oral Implantol* 2010;36:315–324.
18. Cecchinato D, Olsson C, Lindhe J. Submerged or non-submerged healing of endosseous implants to be used in the rehabilitation of partially dentate patients. *J Clin Periodontol* 2004;31:299–308.
19. Cecchinato D, Bengazi F, Blasi G, Botticelli D, Cardarelli I, Gualini F. Bone level alterations at implants placed in the posterior segments of the dentition: Outcome of submerged/non-submerged healing. A 5-year multicenter, randomized, controlled clinical trial. *Clin Oral Implants Res* 2008;19:429–431.
20. Lazzara RJ, Porter SS. Platform switching: A new concept in implant dentistry for controlling postrestorative crestal bone levels. *Int J Periodontics Restorative Dent* 2006;26:9–17.
21. Chrcanovic BR, Albrektsson T, Wennerberg A. Immediately loaded non-submerged versus delayed loaded submerged dental implants: A meta-analysis. *Int J Oral Maxillofac Surg* 2015;44:493–506.